

Partial Ear Reconstruction Using the Eighth Costal Cartilage after Multiple Chondrotomies

MOSTAFA ELSONBATY, M.D.; MOHAMMED ABDELRAHIEM, M.D. and MAURICE FEKREY, M.D.

The Department of Plastic Surgery, Faculty of Medicine, Assiut University, Egypt

ABSTRACT

Aim: The aim of the article is to report our experience with the use of the eighth costal cartilage after shaping it by multiple linear and wedge chondrotomies to reconstruct helical ear defects.

Material and Methods: A review of 14 consecutive cases of partial auricular reconstructions for post traumatic ear defects that was conducted at the Plastic Surgery Department of Assiut University Hospital-Egypt, during the period from January, 2009 to January 2014.

Results: A total of 14 patients with variable degrees of post traumatic partial defects of the ear were included. Median age was 23 years. The male to female ratio was 2.5:1. The cause of the defects was human bites (n=6), burns (n=4) and partial avulsion and lacerations (n=4).

Transverse defects in the form of the upper third ear defect was (n=5), upper and middle third (n=3). And vertical ear defects was (n=4), all including helix only, in addition to secondary correction for near total post-burn missed ear (n=2).

Two stage repair was carried out for reconstruction of these defects, with using the eighth rib costal cartilage as a helical frame in the first stage.

Conclusions: Reconstruction of partial auricular defects represents a challenge to the reconstructive surgeon. The use of autogenous rib cartilage continues to be the gold standard for ear reconstruction. The goal is to reconstruct the partial ear defect to be as near normal as possible with minimal morbidity of the donor site. Each defect is unique and should be evaluated individually.

INTRODUCTION

The projection of the auricle, exposes it to traumatic injuries. Partial auricular defects are commonly developed secondary to traffic road accidents, human and animal bites burns and after surgical excision of ear malignancies [1,2]. In reconstructing the auricle, specific attention must be paid to the contralateral ear if unaffected. The goal is to reconstruct an ear that is symmetric to the opposite side and as near normal as possible.

The use of autogenous rib cartilage continues to be the gold standard for ear reconstruction. In 1920, Gillies was using autologous cartilage for total ear reconstructions [3]. In 1959, Tanzer was the principle promoter of its use and he popularized it with his many articles [4]. In 1987, Brent advanced the standards of ear reconstruction with autogenous materials and was the first to report the successful use of tissue expansion in reconstruction of the ear [5]. In 1992, Nagata's technique modified the incision and framework and made the process into two stages [6]. Firmin has continued to perfect the technique used by Brent and Nagata and obtains spectacular results [7].

Many of the innovative techniques used for total reconstruction of congenital ear defects can be applied to acquired defects.

Several different techniques for partial auricular reconstruction have been described [8-10]. The decision as to which technique is used depends on the size, the injured soft tissue components, and the location of the defect. Patient preferences and the surgeons experience. Each case of auricular reconstruction is unique and all the above parameters must be taken into consideration.

PATIENTS AND METHODS

This study was conducted upon 14 patients at the Plastic Surgery Department of Assiut University Hospital, Egypt, from January 2009 to January 2014. All patients suffering from acquired ear defects were included in the study. Acquired ear defects that required total ear reconstruction are excluded from the study. All procedures were carried out under general anesthesia for the first stage of harvesting the rib graft, shaping it and parrying it in the post-auricular pocket, and local infiltrative anesthesia with 2% xylocain with adrenalin in a concentration of (1:200000), for the second stage.

A subcostal incision about 5cm is made along the floating eighth rib after its determination by palpation to mark the site of the incision. Separation of the overlying muscles is carried out to expose the rib, a sub perichondrial dissection of the eighth costal cartilage with delivery of the distal part of the rib is done, the required length is harvested, usually about 7cm. Closure of the wound in layers without drainage is done (Fig. 1-A,B,C).

To mold the stiff costal cartilage, multiple wedges of cartilage with decreasing size are removed from the inner side of the graft, in addition to multiple linear cuts decreasing in length as we go toward the tip of the rib graft in the outer side, these cuts are alternating with the removed wedges of the other side. The number of the wedges and cuts depends on the extent of molding (Fig. 1-D, E).

A pattern for the construct is made by a piece of X-ray film against the normal ear and tracing its anatomic landmarks. The template is then reversed and made 3mm. Smaller to accommodate for the thickness of the skin cover.

Dissection of the post-auricular pocket according to the template is made with the preservation of good vascular skin cover. The prepared helical graft is then placed into the subcutaneous pocket through an incision located at the root of the helix just above the tragus without drainage.

Second stage is done 3 to 6 months later. In the second stage the construct is elevated to achieve projection of the helical rim. A curved incision is made few millimeters from the margin of the rim and dissection is carried out over the capsule of the construct until the correct amount of projection is achieved, the post-auricular skin defect is then

covered with thick-split thickness skin graft with tie-over (Fig. 2).

Also the harvested graft from the eighth costal cartilage was used to correct resorption of the cartilage in the previously reconstructed post-burn missed ear (Fig. 3).

RESULTS

A total of 14 patients with variable degrees of post traumatic partial defects of the ear were included in this study. The age of the patients was ranged between 16 and 36 years old with a mean of 23 year old. Ten patients were males and four were females. The male to female ratio was 2.5:1. The cause of the defects was human bites (n=6), burns (n=4) and partial avulsion and lacerations (n=4).

Transverse defects in the form of the upper third ear defect was (n=5), upper and middle third (n=3). And vertical auricular defects was (n=4), all including helix only, in addition to two patients coming for secondary correction of the previously reconstructed near total post-burn missed auricle with resorption of the cartilaginous frame. Table (1).

The average time for harvesting the eighth costal cartilage was 30 minutes. The average length of the chest incision was 5cm. No drains were used during any of the operation stages. No chest complications secondary to rib harvesting were reported, except minimal pain at the donor site, which was relieved by oral analgesics.

Follow-up of these patients varied between 6 and 12 months, Pre and post-operative photos, in addition to late follow-up photos for assessment of the results were taken.

Table (1): Age, sex, cause and site of auricular defects.

Age	Sex	Cause of auricular defect	Site of the defect
16	Female	Partial avulsion and lacerations	Vertical
19	Male	Human bite	Upper third
20	Male	Partial avulsion and lacerations	Vertical
22	Female	Burn (secondary correction)	Near total defect
23	Male	Human bite	Upper third
21	Male	Partial avulsion and lacerations	Upper and middle third
36	Male	Burn (secondary correction)	Near total defect
30	Male	Human bite	Upper third
20	Male	Partial avulsion and lacerations	Vertical
22	Male	Human bite	Upper third
18	Female	Burn	Upper and middle third
27	Male	Human bite	Vertical
25	Female	Burn	Upper and middle third
23	Male	Human bite	Upper third

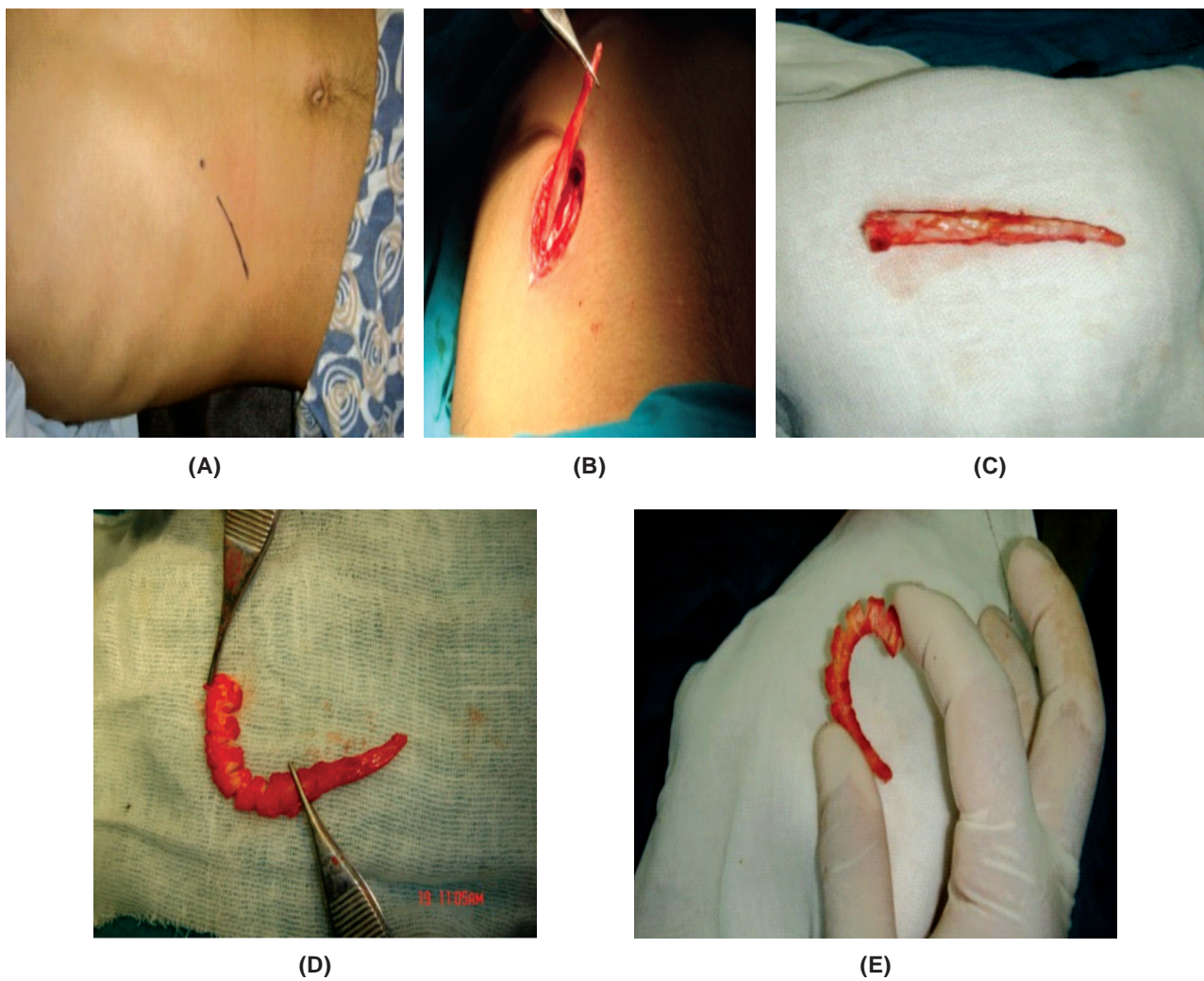


Fig. (1): Harvesting and shaping of the eighth costal cartilage, (A) Skin incision along the eighth costal cartilage determined by palpation. (B) Exposure and delivery of the cartilage. (C) The harvested cartilage. (D) Linear chondrotomies in the outer sides and wedge chondrotomies in the inner side. (E) The final shaping of the cartilage graft.

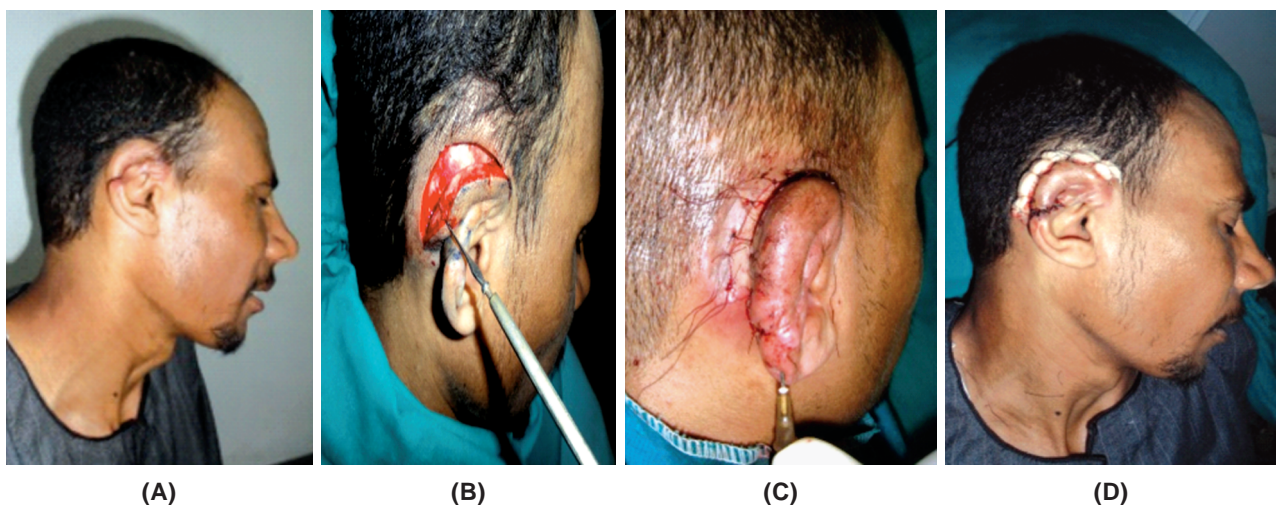


Fig. (2): Partial auricular reconstruction using eighth costal cartilage graft and post auricular skin. (A) Shaped cartilage graft buried in the post-auricular region. (B) Elevation of the reconstructed ear. (C) Skin graft with tie-over. (D) Reconstructed ear after the first dressing.

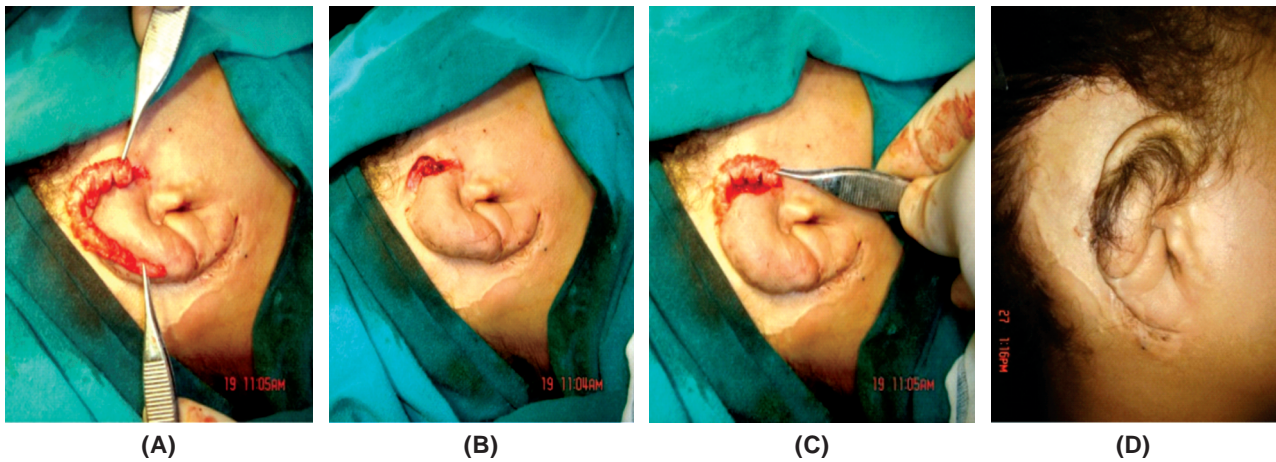


Fig. (3): The use of the eighth costal cartilage graft to improve the previously reconstructed post burn missed ear, (A) The shaped cartilage graft. (B) Incision in the upper pole for insertion of the graft. (C) Partially introduced graft. (D) Late post-operative result with hairs in the reconstructed ear.

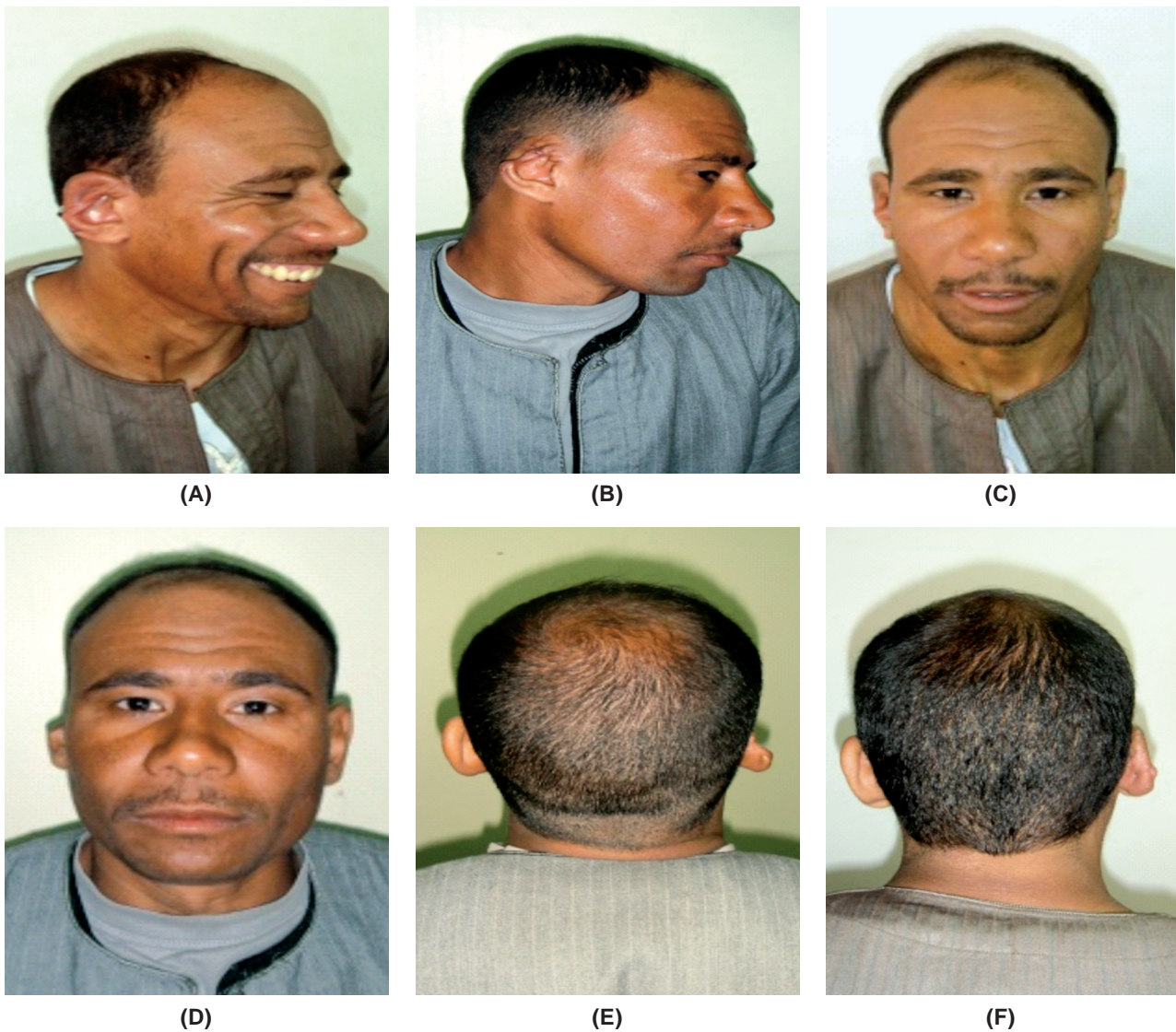


Fig. (4): A 30 years old patient with loss of the upper third of the auricle secondary to human bite. (A,B) Pre and post-operative oblique view after auricular reconstruction using eighth costal cartilage as a frame. (C,D) Anterior view. (E,F) Posterior view.

DISCUSSION

A total of 14 patients with variable degrees of post traumatic partial defects of the ear were included in this study. The age of the patients was ranged between 16 and 36 years old with a mean of 23 year old. Ten patients were males and four were females. Male to female ratio was 2.5:1. Causes of the defects were human bites (n=6), burns (n=4) and partial avulsion and lacerations (n=4).

Transverse defects in the form of the upper third ear defect was (n=5), upper and middle third (n=3). And vertical ear defects was (n=4), all including helix only, in addition to two patients coming for secondary correction of the previously reconstructed near total post-burn missed ear with resorption of the cartilaginous frame.

The average time for harvesting the eighth costal cartilage was 30 minutes. The average length of the chest incision was 5cm. No drains were used during any of the operation stages. No chest complications secondary to rib harvesting were reported, except minimal pain at the donor site, which was relieved by oral analgesics.

Follow-up of these patients varied between 6 and 12 months, Pre- and post-operative photos, in addition to late follow-up photos for assessment of the results were taken.

Conclusion:

Reconstruction of partial auricular defects represents a challenge to the reconstructive surgeon. The use of autogenous rib cartilage continues to be the gold standard for auricular reconstruction. The goal is to reconstruct the partial auricular defect to be as near normal as possible with minimal morbidity of the donor site. Each defect is unique and should be evaluated individually.

REFERENCES

- 1- Cheney M.L., Hadlock T.A. and Quatela V.C.: Reconstruction of the auricle. In: Baker S.R., editor. Local flaps in facial reconstruction. Edinburgh: Elsevier Mosby, pp. 581-624, 2007.
- 2- Park S.S. and Hood R.J.: Auricular reconstruction. *Otolaryngol. Clin. North. Am.*, 34 (4): 713-738, 2001.
- 3- Gillies H.D.: Reconstruction of the external ear with special reference to the use of maternal ear cartilage as the supporting structure. *Rev. Chir. Structiv*, 7: 169-179, 1937.
- 4- Tanzer R.C.: An analysis of ear reconstruction. *Plast. Reconstr. Surg.*, 31: 16-30, 1963.
- 5- Brent B.: Technical advances in ear reconstruction with autogenous rib cartilage grafts: Personal experience with 1200 cases. *Plast. Reconstr. Surg.*, 104: 319, 1999.
- 6- Nagata S.: A new method of total reconstruction of the auricle for microtia. *Plast. Reconstr. Surg.*, 92: 187, 1993.
- 7- Firmin F.: Ear reconstruction in cases of typical microtia. Personal experience based on 352 microtic ear corrections. *Scand. J. Plast. Reconstr. Surg. Hand Surg.*, 32: 35, 1998.
- 8- Ellabban M., Maamoun I. and Elsharkawi M.: The bipedicle post-auricular tube flap for reconstruction of partial ear defects, *British Journal of Plastic Surgery*, 56, (6): 593-598, 2003.
- 9- Cheney M.L., Hadlock T.A. and Quatela V.C.: Reconstruction of the auricle. In: Baker S.R., editor. Local flaps in facial reconstruction. Edinburgh: Elsevier Mosby, pp. 581-624, 2007.
- 10- Park S.S. and Hood R.J.: Auricular reconstruction. *Otolaryngol. Clin. North. Am.*, 34 (4): 713-738, 2001.
- 11- Uppal R.S.1, Sabbagh W., Chana J. and Gault D.T.: Donor-site morbidity after autologous costal cartilage harvest in ear reconstruction and approaches to reducing donor-site contour deformity. *Plast. Reconstr. Surg.*, 121 (6): 1949-55, 2008.
- 12- Kawanabe Y.1 and Nagata S.: A new method of costal cartilage harvest for total auricular reconstruction: Part I. Avoidance and prevention of intraoperative and post-operative complications and problems. *Plast. Reconstr. Surg.*, 117 (6): 2011-18, 2006.
- 13- Michael Lee, M.D., Jared Inman, M.D. and Yadranko Ducic, M.D., F.A.C.S.: Central Segment Harvest of Costal Cartilage in Rhinoplasty Laryngoscope, 121: 2155-2158, 2011.
- 14- Gault D.: Treatment of unwanted hair in auricular reconstruction. *Facial. Plast. Surg.*, 25 (3): 175-80, 2009.
- 15- Siegert R. and Magritz R.: Special reconstruction techniques for special circumstances. *Facial. Plast. Surg.*, 25 (3): 204-11, 2009.